

Case

Dr Siphso Dlamini

Division of Infectious Diseases & HIV Medicine
University of Cape Town
Groote Schuur Hospital

Ms DS

Background History

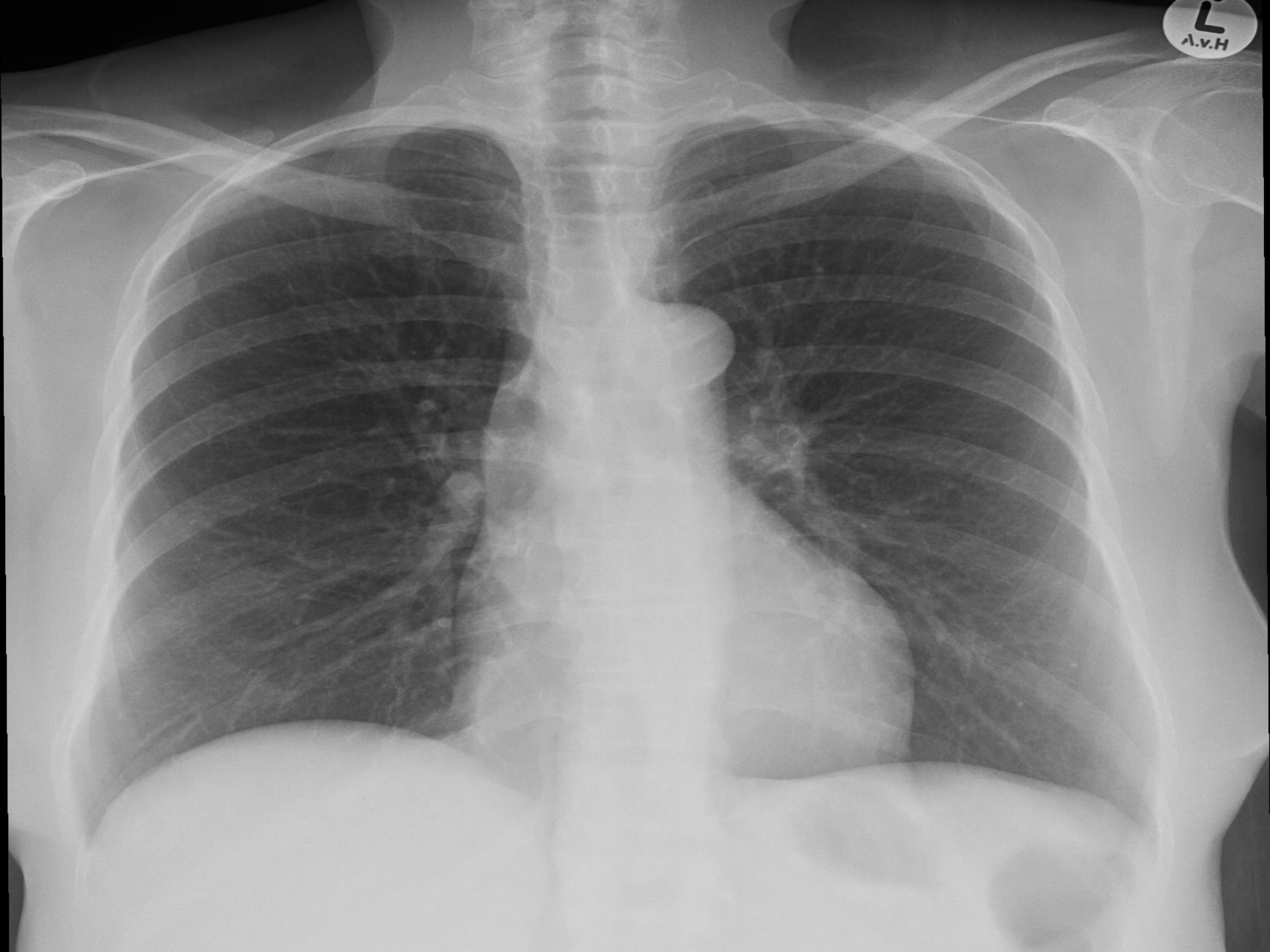- 54 yr old
- HIV +ve on ART since 2009
 - Lamzid (AZT + 3TC) & Efavirenz
 - CD4⁺ count 773 VL-LDL
- Hypertension
 - Enalapril, amlodipine, & hydrochlorothiazide.
- Other medication
 - Atorvastatin
 - Amitriptyline

Clinic referral

- Unexplained weight loss
 - 14 kg loss over 4 months (81-67 kg)
 - No other symptoms
- Investigations
 - TB (GeneXpert & culture) –ve
 - U/S – normal
 - LFT: ↑ALP 418, ↑GGT 399

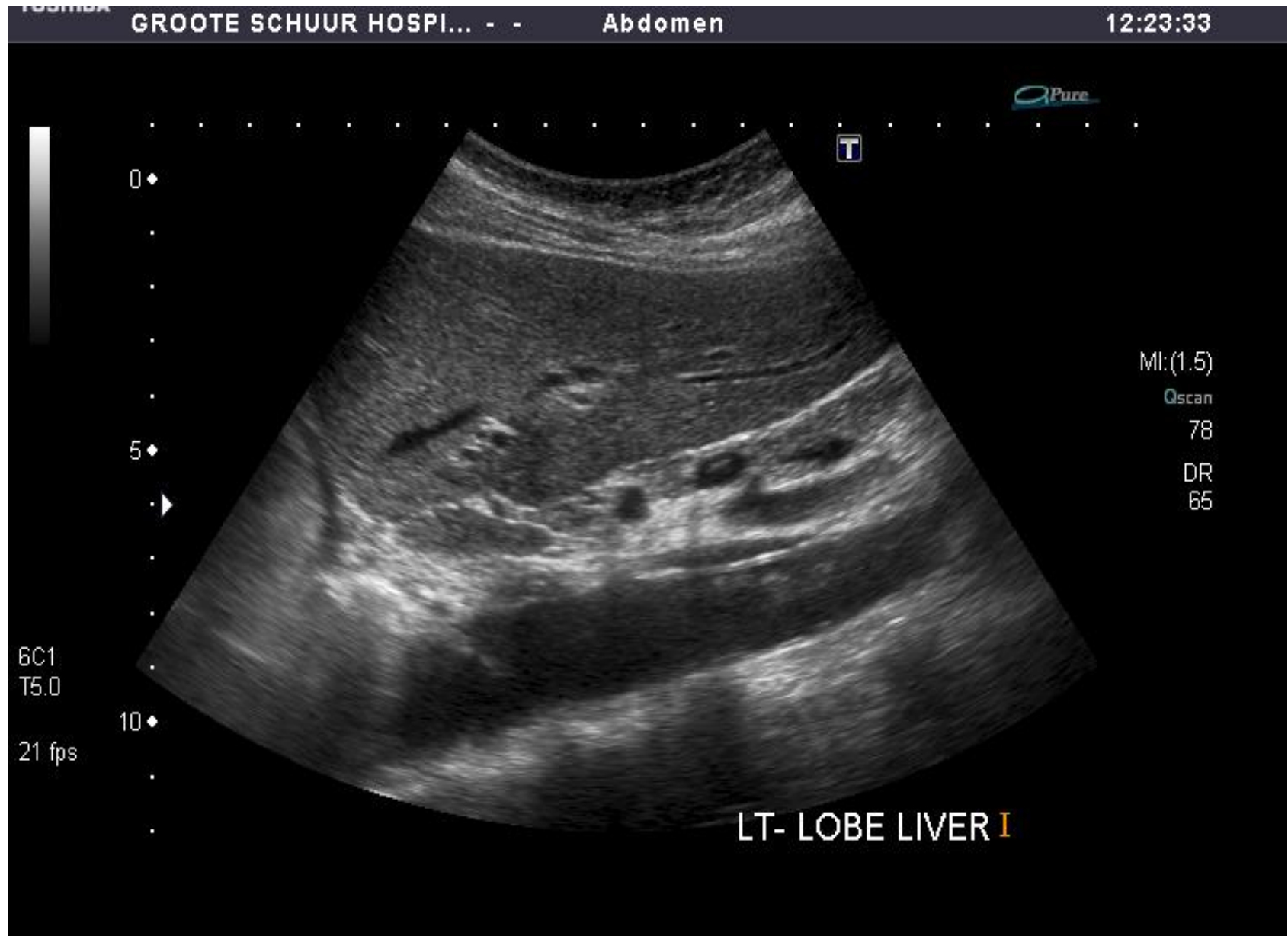Clinical Examination

- BMI 26, weight 67kg, BP= 132/88 mmHg, T 36.3°C
- Facial lipoatrophy
- Absent tendon reflexes
- Rest of examination normal



L
A.V.H.

Ultrasound findings



Summary

- HIV +ve CD4⁺ 773 on ART VL-LDL
 - Lamzid + EFV
 - Features of lipoatrophy
- Hypertension – well controlled
- Now with unexplained weight loss

What are the possible causes of her weight loss?

- A. Tuberculosis
- B. Malnutrition
- C. Metabolic consequences of ART
- D. Chronic infection

Investigations

WCC	6.31 X 10 ⁹ /L
Hb	11 g/dl
MCV	118 fl
PLT	599 X 10 ⁹ /L
Neutrophils	3.45 X 10 ⁹ /l

TB	6 µmol/l
TP	87 g/l
Alb	42 g/l
ALP	394 u/l
GGT	401 u/l
ALT	46 u/l
AST	85 u/l
Creat	60 µmol/l

Triglycerides	0.6 mmol/l
Cholesterol	5.0 mmol/l
Syphilis	RPR -ve
TSH	1.28 mIU/l (0.27-4.20)
FT3	4.2 pmol/l (2.8-7.1)
FT4	12.0 pmol/l (12-22)
CRP	53.9 mg/l
Lactate	0.7 mmol/l
Glucose (fasting)	5.0 mmol/l
Viral load	LDL

Any more thoughts Panel?



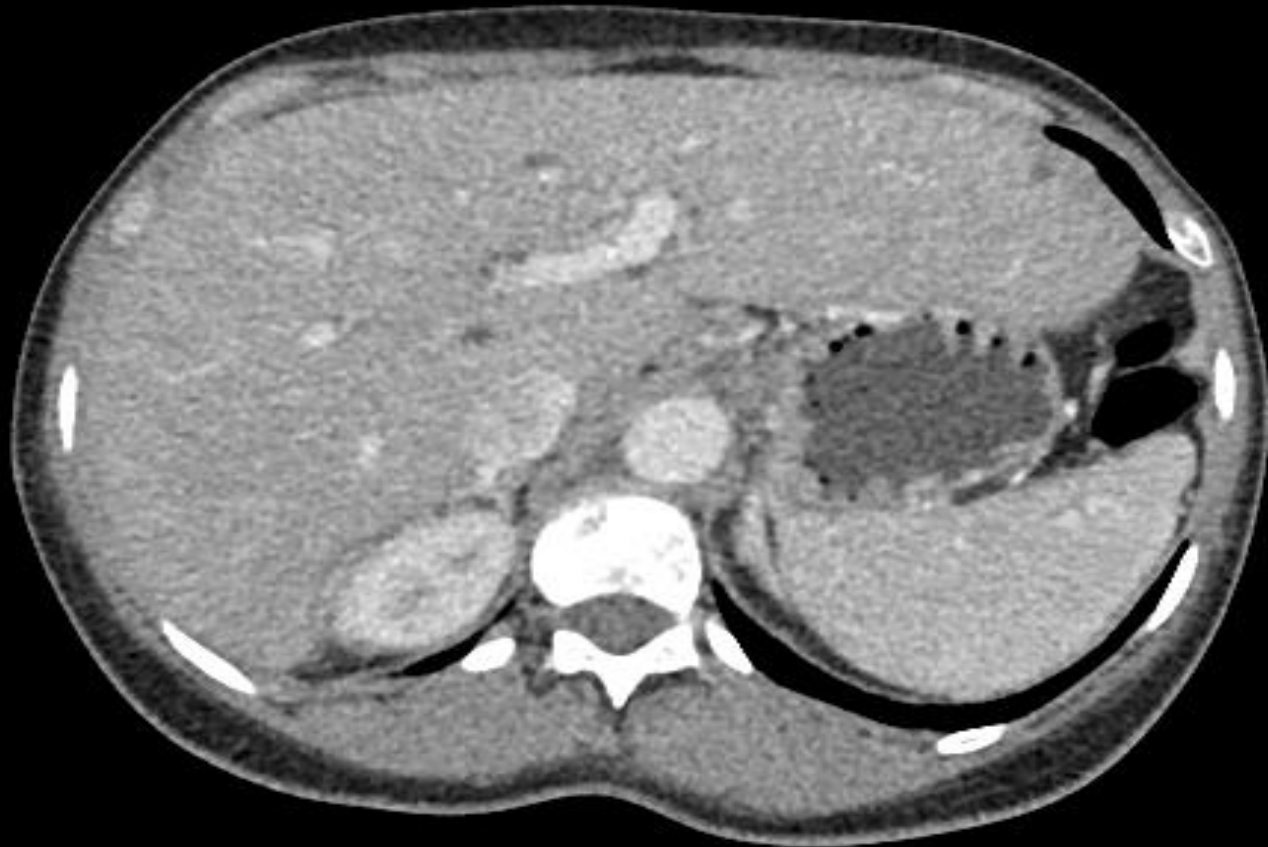What do you do about her ART?

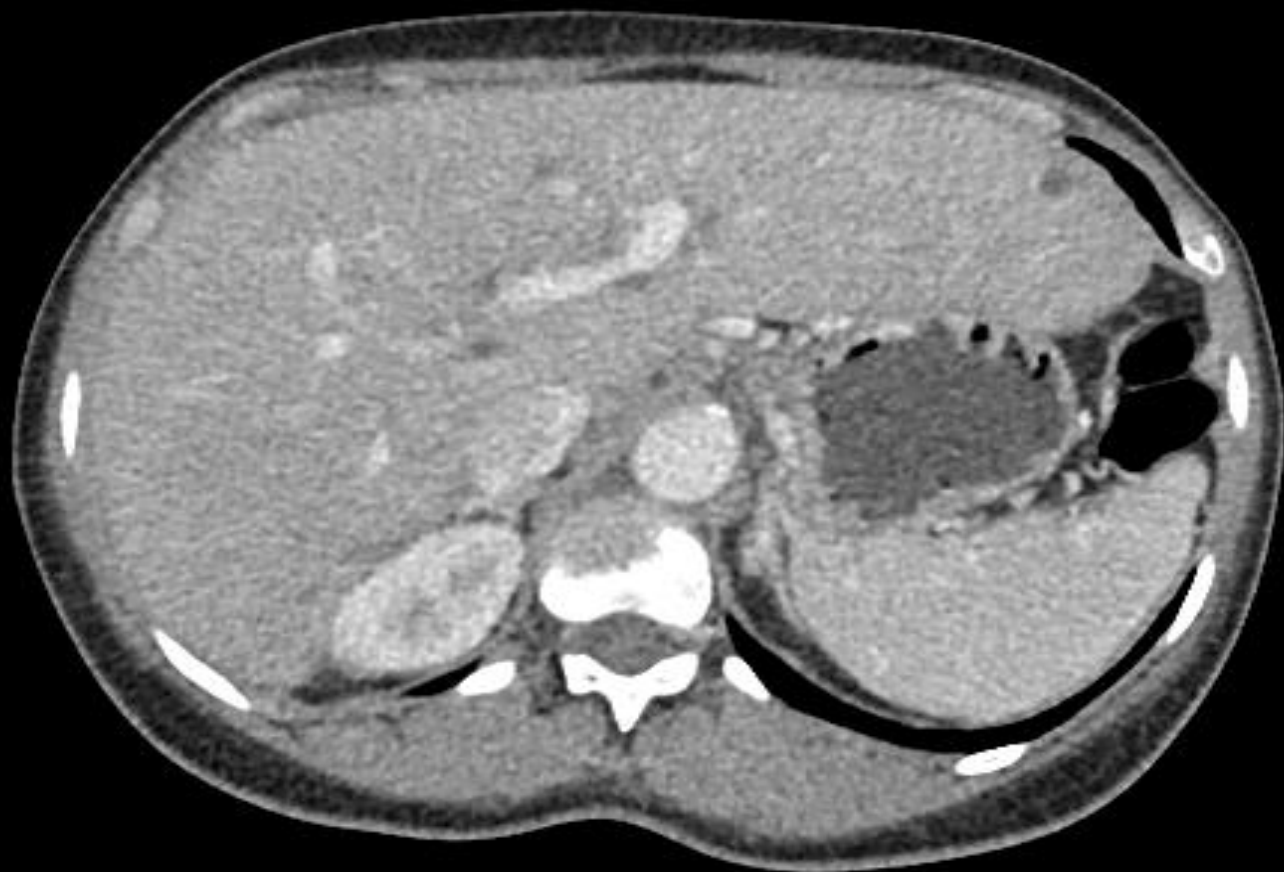- A. Nothing
- B. Switch Zidovudine (AZT) for Tenofovir (TDF)

Question

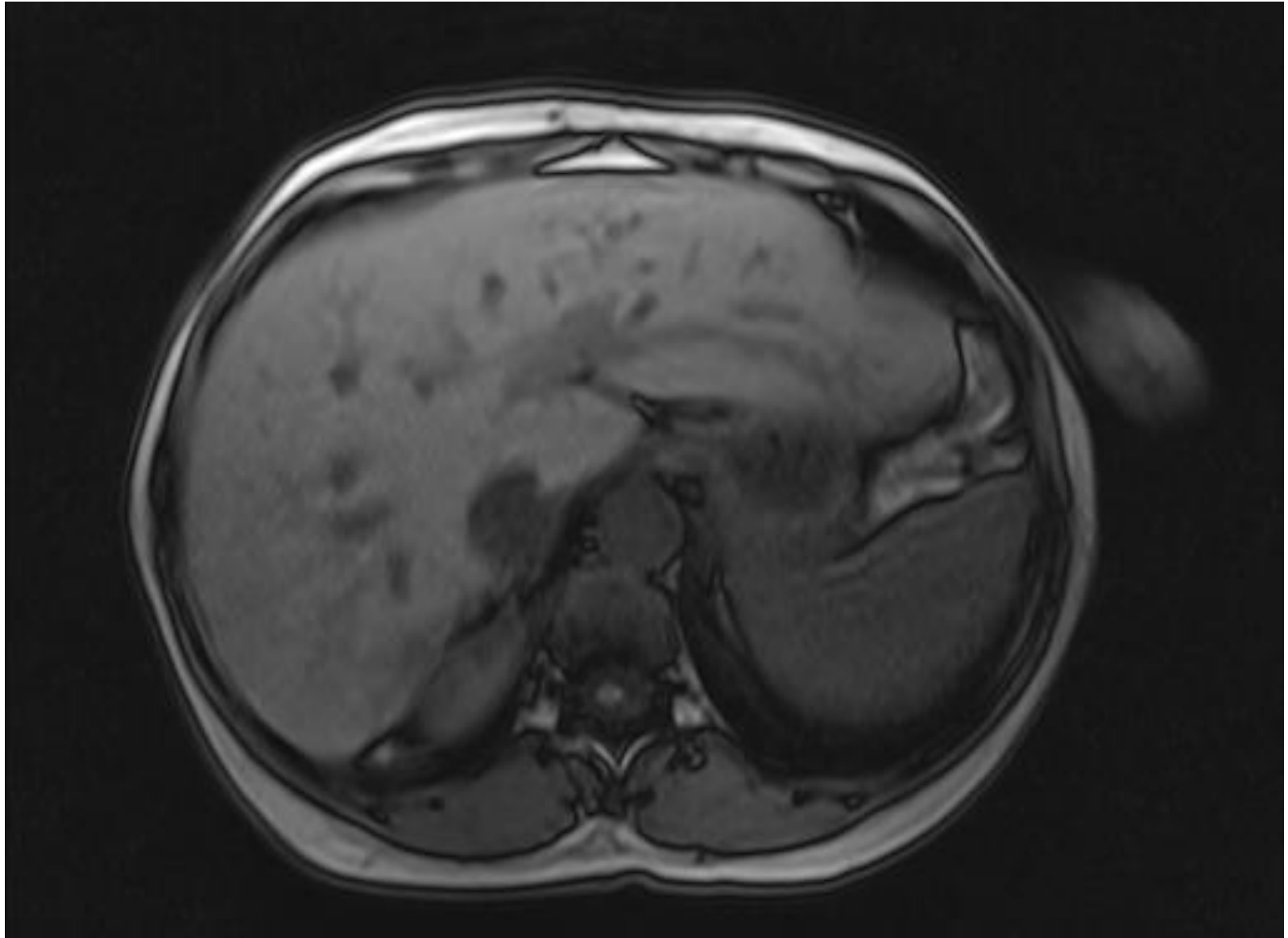
3. What further tests would you do now?

CT Abdomen





MRCP



Liver Biopsy Result

- Microabscess with numerous neutrophils & foamy macrophages
- Ductular proliferation surrounding the abscess
- Portal tracts with lymphoid aggregate
 - Sparse inflammatory infiltrate of plasma cells, eosinophils & lymphocytes
- Portal-portal bridging fibrosis

Any more thoughts Panel?



Final Diagnosis & Outcome

- Liver microabscesses
 - Treated with antibiotics
- Eosinophilic inflammation
 - Drug injury ? Efavirenz
 - Efavirenz switched for Lopinar/Ritonavir (Aluvia)
- Reviewed 4 months later
 - Doing well
 - Weight now 80kg
 - LFT: ALP 99 u/l , GGT 50 u/l



**KEEP
CALM
AND
THANK
YOU**